



**PATIENT**

Ashtyn BHS

**SPECIES**

Feline

**BREED**

DSH

**SEX**

Female Intact

**AGE**

2 years

**WEIGHT**

6.6lbs

**INTERPRETED BY**

Maggie Machen Lamy,  
DVM DACVIM  
(Cardiology)

**IMAGING PERFORMED BY**

Kelly Reschny, RVT

**PRESENTING CLINICAL SIGNS**

History: Dynamic heart murmur with grade affected with HR. When more nervous/higher HR around 160-180 it is a grade 3 murmur but as HR decreases murmur grade reduces and is absent with lower heart around 120-130. Most prominent a little parasternal on either side. Cat was standing during all auscultations. HR 180, RR 32.

**ECHOCARDIOGRAM FINDINGS**

2D, m-mode, color flow and doppler imaging is available. The left ventricular wall is normal in dimension. There is a mildly hyperechoic endocardium consistent with mild fibrosis. The papillary muscles are normal in size and hyperechoic. The endocardium appears normal. The left atrium is normal in size. The right atrium is normal in size. The right ventricle appears normal. The mitral valve is normal in structure and mobility. Normal flow through both the RVOT and LVOT. No TR, AI or PI. No pleural or pericardial effusion seen. No obvious cardiac tumors.

**CARDIAC CHART**

| FELINE CARDIAC PARAMETERS                                                                                                                                                                                                                                                                                          | BODY WEIGHT (kg) | HR (BPM)                        | IVSd (cm) (Moise, Pipers)                | LVIDd (cm) (Moise, Pipers) | LWVd (cm) (Moise, Pipers) | FS (%)         | EF (%)      |
|--------------------------------------------------------------------------------------------------------------------------------------------------------------------------------------------------------------------------------------------------------------------------------------------------------------------|------------------|---------------------------------|------------------------------------------|----------------------------|---------------------------|----------------|-------------|
| NORMAL PARAMETER                                                                                                                                                                                                                                                                                                   | -----            | 150-240                         | 0.35-0.55                                | <2 (mean 1.5)              | 3.5-0.55                  | 35-67          | 80-100      |
| PATIENT                                                                                                                                                                                                                                                                                                            | 3.0              | 160                             | 0.37                                     | 1.3                        | 0.40                      | 50             | 92          |
| FELINE CARDIAC PARAMETERS                                                                                                                                                                                                                                                                                          | LA/AO (Boon)     | LA/AO HEART BASE (Swe) (Abbott) | LA 2D short axis Base view (cm) (Abbott) |                            | LVOT VEL (m/s)            | RVOT VEL (m/s) | E max (m/s) |
| NORMAL                                                                                                                                                                                                                                                                                                             | <1.5             | <1.3                            | <1.2                                     |                            | <1.6                      | <1.3           | <0.9        |
| PATIENT                                                                                                                                                                                                                                                                                                            | 1.3              | 1.2                             | 1.0                                      |                            | 1.2                       | 0.95           | NM          |
| <p><i>*Note: All measurements based upon multi-modal images and methods. An average value is reported.</i><br/>Adapted from June Boon, Veterinary Echocardiography, 1998<br/>Abbott J &amp; MacLean H JVIM 2006;20: 111-119, Moise et al. Am J Vet Res 47:1476, 1986. Pipers et al. Am J Vet Res 40:882, 1979.</p> |                  |                                 |                                          |                            |                           |                |             |

**HOSPITAL NAME**

Burlington Humane Society

**REFERRING VET**

Dr. Hall

**INVOICE**

23500

**DATE**

4/6/22

**INTERPRETATION OF THE FINDINGS & FURTHER RECOMMENDATIONS**

Overtly normal cardiac structure and function. The LV wall thickness is normal and there is no evidence of elevated left atrial pressure. No obvious congenital issues are documented. No cause for the murmur is identified in this study, making it likely physiologic in origin. Should the murmur persist or progress significantly, referral to a local Cardiologist may be warranted.

Given these findings, no medications are indicated. It is important to note that phenotypic HCM can develop at any phase of life in cats (particularly in this predisposed breed), and often does not accompany a heart murmur or PE abnormalities. Periodic screening is ideally recommended in all cats.

No cardiac contraindication for general anesthesia at this time.



**PATIENT**

Ashtyn BHS

Recommend recheck echocardiogram in 1 year to assess for development of disease, sooner if a murmur/gallop or clinical signs develop in the interim.

**SPECIES**

Feline

**BREED**

DSH

**SEX**

Female Intact

**AGE**

2 years

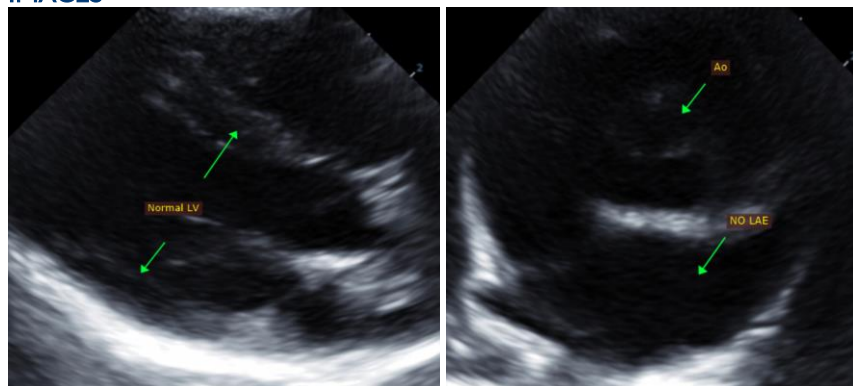
**WEIGHT**

6.6lbs

**INTERPRETED BY**

Maggie Machen Lamy,  
DVM DACVIM  
(Cardiology)

**IMAGES**



The information and recommendations provided are based on the images presented by the referring veterinarian. No evaluation can be communicated regarding pathology that was not visible in the image/video clips provided.

Thank you for this referral. This report was generated using transcription software, and minor dictation errors may be present. If the clinical or image interpretation does not parallel your findings or if I can be of any further assistance, please contact me.

Maggie Machen Lamy, DVM

Diplomate of the American College of Veterinary Internal Medicine (Cardiology)

info@sonopath.com

**IMAGING PERFORMED BY**

Kelly Reschny, RVT

**HOSPITAL NAME**

Burlington Humane  
Society

**REFERRING VET**

Dr. Hall

**INVOICE**

23500

**DATE**

4/6/22